

## **Vein Graft Versus Silicone Tube as a Conduit for Peripheral Nerve Defects: An Experimental Study**

LOAI EL-BASSIONY, M.D.\*; KHALED EL-MOSALEMY, M.D.\*\* and NASHWA M. BARAKAT, Ph.D.\*\*\*

*The Departments of Plastic Surgery\*, Mansoura University; Histology\*\*, Zagazig University and Veterinary Medicine\*\*\*, Research Institute, Urology Center, Mansoura University.*

### **ABSTRACT**

Restoration of normal nerve function following nerve injury has remained a persistently elusive goal. The limited availability of donor sites for autogenous nerve grafts and their associated morbidity continue to stimulate research toward finding suitable alternatives. The purpose of this study was to determine the efficacy of autogenous vein graft as a nerve conduit for bridging small nerve gaps as compared with conventional nerve grafting technique. Also, the possibility for application of synthetic silicone tube as a conduit for similar nerve gap was elucidated. A 10-mm segment of a unilateral sciatic nerve of 32 adult male Sprague-Dawley rats was excised. Rats were classified into 3 groups: Group I (n=8): The excised nerve segment was reappplied as a traditional nerve graft and sutured epineurially. Group II (n=12): The neural gap was crossed with a 15-mm segment of autogenous external jugular vein. Group III (n=12): The gap was crossed with a 15-mm silicone tube. Specimens were harvested from the middle of the conduit after 3 months and examined histologically by light and transmission electron microscopes. Proper neural regeneration was evident in the vein graft group as compared to the nerve graft one. Minimal fibroblasts were detected in some specimens of the venous conduit that did not alter the overall accepted healing. No evidence of neural regeneration was detected with the use of silicone tube. Therefore, autogenous vein graft is a suitable alternative for nerve graft to manage short nerve defects. Also, the non-absorbable silicone material seems not to enhance neural regeneration inside for rat nerve defects more than 10mm. Hence, the use of biocompatible materials to fabricate nerve conduits is encouraged.

### **INTRODUCTION**

The surgical management of injured peripheral nerves where a gap is present still remains a formidable problem in reconstructive surgery. Bridging the nerve gap by the interposition of an autogenous nerve graft is the current treatment of choice for such situation [1]. However, the limited availability of donor sites for nerve grafts (sural nerve, approximately 25-30cm), the potentially inappropriate diameter of around 1.5mm of most selected nerves, and their inherent associated morbidity or neuroma

formation continue to stimulate researches toward finding a suitable alternative to bridge a gap and to enhance the process of peripheral nerve regeneration.

Many factors determine the success of neural regeneration [2]. The immediate neural environment plays the main role. It comprises various cellular components, such as Schwann cells and perineural fibroblasts; extracellular matrix components, such as laminin, fibronectin and neural adhesion molecules and neurotrophic factors that are produced by the transected nerve stump, such as nerve growth factor (NGF), fibroblast growth factor (B-FGF), neurotrophin-3 (NT-3), brain-derived neurotrophic factor (BDNF) and c-AMP [3-5]. So, having a suitable chamber to keep these components within the nerve gap should allow proper neural regeneration across the defect.

The use of autogenous venous conduits for nerve repairs has been an old idea. That epochal event traces back to Bungner's bridging of a canine sciatic nerve gap with brachial artery in 1891 [6]. Next trials showed some failures as resorption of the vessel graft and penetration of the regenerating neural tissue through the vessel wall [7,8]. Such failure retarded the evolvement of the concept of using non-neural biological bridge graft technique for a time. Gibb [9], in 1970, reported the use of vein graft to protect facial nerve repair with favorable results. Later, in 1980, Chiu et al. [10] presented histological and electrophysiological evidences for rat sciatic nerve regeneration across a 10-mm gap through a vein graft. From that point researches started to confirm and refine this new technique to use an interpositional autogenous vein graft to provide a protected passage for neural regeneration [11-13].

Silicone polymer is a high molecular weight compound made of silicon, oxygen and hydrogen. It is hydrophobic and considered physiologically well accepted [14]. Silicone tubulation models have been used to bridge a 10-mm nerve deficit in rats [15] and rabbits [16]. Prefilling of the silicone tube with plasma allowed rat sciatic nerve regeneration across a 15-mm gap [17].

A method of nerve repair that would minimize surgical trauma, prevent interference of nerve growth with scar tissue and allow manipulation of the regenerative efforts of the proximal stump should be a welcome addition to the field of peripheral nerve surgery. In the current experiment, we compare rat sciatic nerve regeneration across a 15-mm defect through nerve graft, vein graft and silicone tube conduits.

## MATERIAL AND METHODS

A total of thirty two adult male Sprague-Dawley rats weighing 300-350gm were utilized in this study. The animals were housed in beta chip-lined plastic cages (one rat per cage) and given food and water ad libitum under the supervision of a trained veterinarian. Surgical procedures were performed under aseptic condition with microsurgical technique by the aid of an operating microscope (Zeiss, Oberkochen, Germany).

### *Operative technique:*

Rats were anesthetized with intraperitoneal injection of ketamine HCl (100mg/kg) plus diazepam (5mg/kg). Supplementary doses were administered as required to maintain a sufficient depth of anesthesia. While the rat is in prone position, an oblique right gluteal skin incision and a muscle splitting access were used to expose the right sciatic nerve from the sciatic notch to the point of its bifurcation (Fig. 1). A 10-mm segment of the sciatic nerve was excised (Fig. 2). Then, the rats were assigned into three groups.

*Group I (control group, n=8):* The resected 10-mm nerve segment was used as a nerve graft and sutured to both stumps with 10-0 Nylon® suture, with conventional epineurial technique.

*Group II (vein graft group, n=12):* The rats were placed supine and the right external jugular vein was exposed through a midline neck incision. A 15-mm segment of the vein was harvested, irrigated with heparinized-saline and reversed end-to-end (to ensure unimpeded axon growth) in preparation for use as a conduit. The neck incision was sutured with 4-0 Silk suture. The rats were placed prone back. The vein wall was sutured to the nerve

stumps epineurium with four 10-0 Nylon® sutures (Fig. 3).

*Group III (silicone tube group, n=12):* A 2-mm silicone medical grade tube, that comes sterile, was cut into 15-mm segments. The tube was sutured to the epineurium of the nerve stumps with four 10-0 Nylon® sutures (Fig. 4).

After finishing the surgical steps, muscles were reapproximated with 4-0 Vicryl® suture and the skin was closed with running 4-0 Vicryl® suture. Rats were allowed to run free in the cages and no drugs were administered.

Evaluation was done after 3 months. Euthanasia was induced by halothane inhalation in a closed box. The operative site was re-exposed and the sciatic nerve was harvested with the intervening nerve, vein, or silicone conduit en block from all rats. The proximal end of the conduit was marked with a black suture. The left sciatic nerve was harvested from three rats to be histologically examined for reference (Fig. 5-A,B).

The nerves were stretched to the in vivo length by being pinned to a chord and were immediately fixed with 2.5% glutaraldehyde buffered in 0.1M phosphate buffer (pH 7.4) for 2-4 hours in 4°C. After fixation, the nerves were rinsed twice in phosphate buffer (pH 7.4) and a tissue block (approximately 1-mm long) was cut from the middle of the regeneration (middle of the nerve, vein and silicone tube). Specimens were dehydrated in ascending grades of ethanol and then were put in propylene oxide for 30 minutes at room temperature. They were impregnated in a mixture of propylene oxide and resin (1:1) for one hour then in the same mixture for one hour at 48°C. These procedures were completed by embedding the tissue in Embed-812 resin in BEEM capsules for 24 hours at 60°C. By the use of an ultramicrotome (Leica, UCT Nubloch, Germany), semithin (1µm) sections from the midpoint of the graft were obtained to be stained with 1% toluidine blue for light microscopic (LM) examination. Also, ultrathin sections were prepared to be stained with uranyl acetate and lead citrate for transmission electron microscopic (TEM) examination (JEOL JEM 1010 electron microscope).

## RESULTS

### *Gross findings:*

During the three months follow-up, two rats from group II and 3 rats from group III died of unknown reason. The 5 rats were replaced.

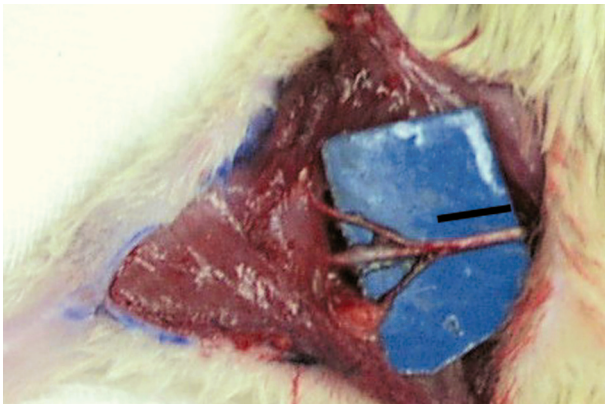


Fig. (1): Sciatic nerve exposure. The black line is opposite the area to be resected.

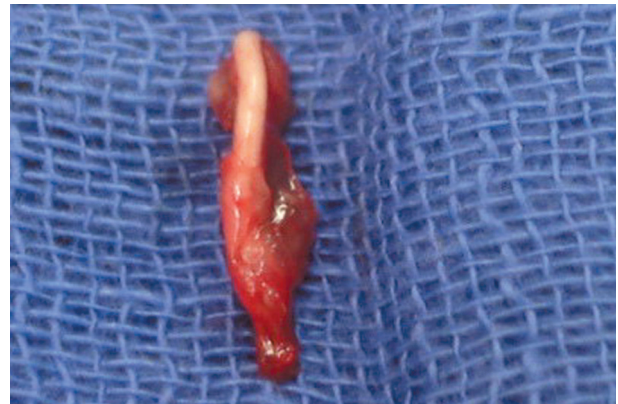

Fig. (2): The resected nerve segment.

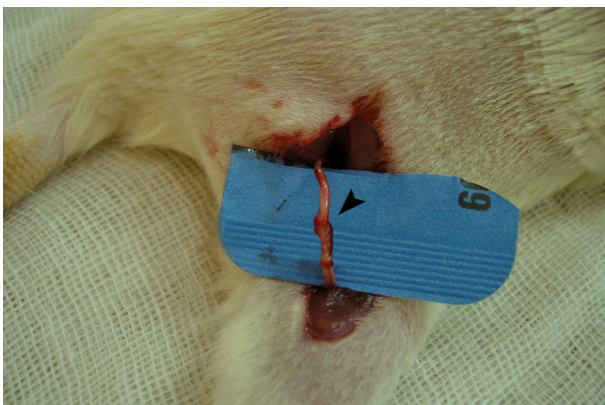


Fig. (3): The vein graft conduit (arrow head) in place before suturing.

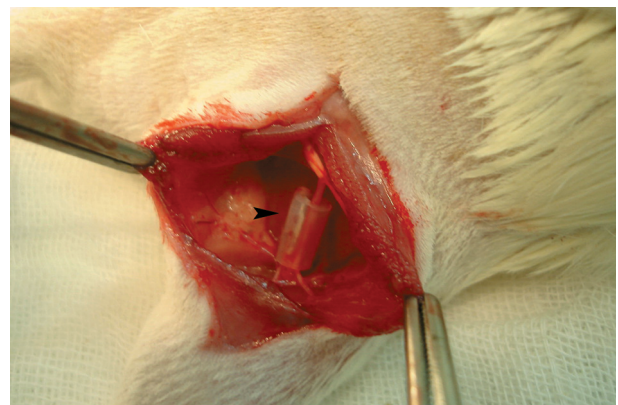


Fig. (4): The silicone tube conduit (arrow head) in place.

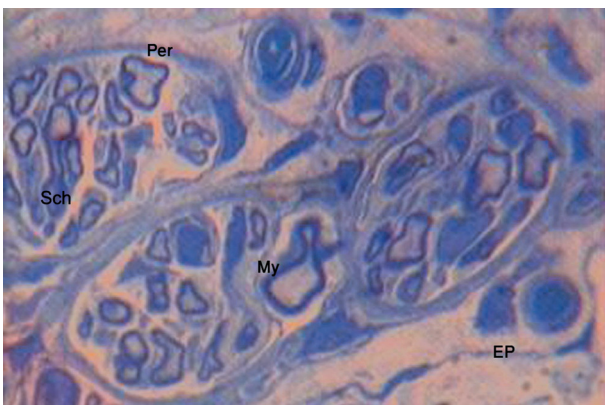


Fig. (5-A): Representative histologic sample from the normal rat sciatic nerve (LM, toluidine blue stain; x1,000). (Sch=Schwann cell, My=myelin, Per=perineurium, Ep=epineurium).

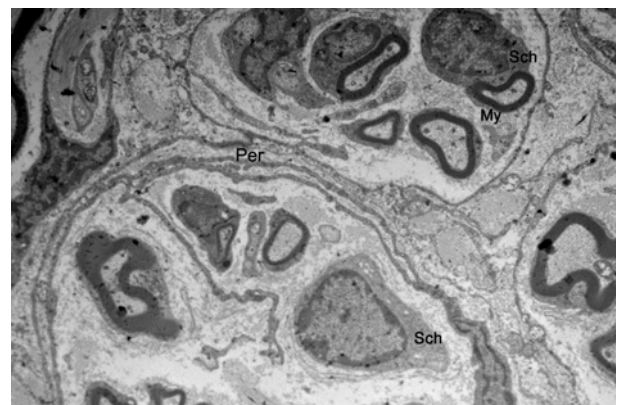


Fig. (5-B): Electron microscopic examination of normal rat sciatic nerve (TEM; x4,000). (Sch=Schwann cell, My=myelin, Per=perineurium).

**Group I:** The sciatic nerve grafts were well healed; with suture lines neuroma formation in 4 rats (out of eight). Proximal and distal stumps appeared normal.

**Group II:** The intact vein graft could be identified connected to distal and proximal nerve stumps without neuroma formation. No neuroma formation at suture line and no adhesions were noticed between the vein/nerve structure and the surrounding connective tissue. The vein walls were not col-

lapsed, firm in consistency indicating some regenerate inside. Proximal and distal nerve stumps appeared normal.

**Group III:** Four specimens (out of twelve) showed disruption of the silicone tube from the nerve at one end. The remaining eight specimens showed solid tissue particle surrounded by a straw-color fluid inside the tube. Marked attenuation of proximal and distal stumps was observed.

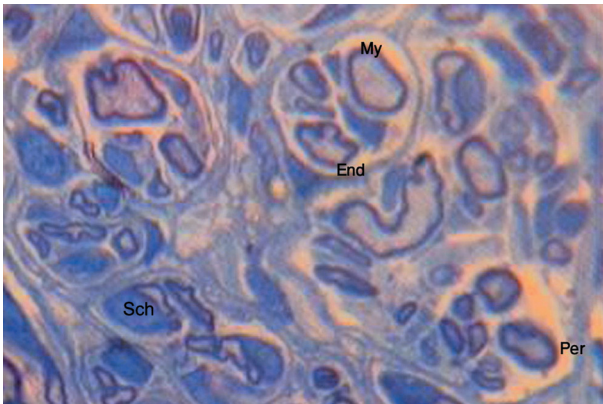


Fig. (6-A): The nerve graft specimen. The nerve fibres are surrounded with myelin (My) and endoneurium (End). Fibers are arranged in multifascicular pattern of different sizes separated by perineurium (Per). Schwann cells (Sch) are abundant (LM, toluidine blue stain; x1,000).

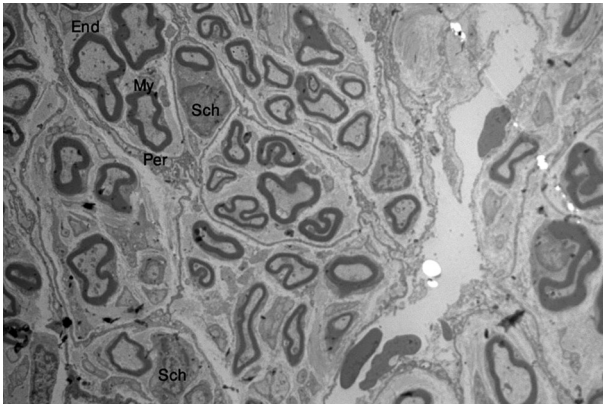


Fig. (6-B): Electron microscopic examination of the nerve graft specimen (TEM; x2,000). (Sch=Schwann cell, My=myelin, End=endoneurium, Per= perineurium).

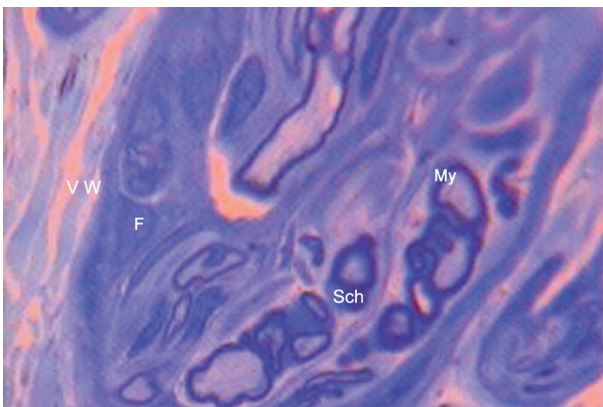


Fig. (7-A): Vein graft specimen. Regenerated myelinated (My) neural tissue is observed with enough Schwann cells (Sch). An outer layer surrounding the epineurial-like element is noticed; the vein graft wall (VW). Some fibroblasts (F) are detected (LM, toluidine blue stain; x1,000).

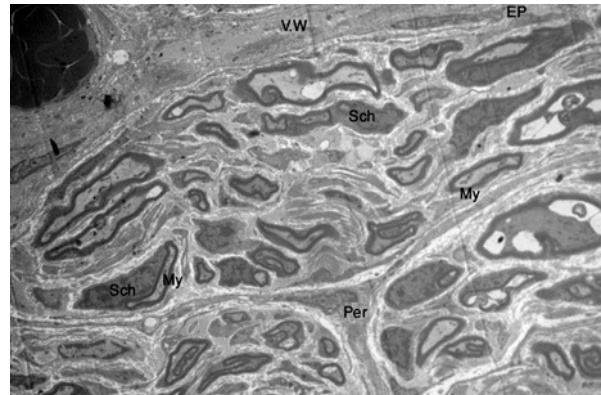


Fig. (7-B): Electron microscopic examination of the vein graft specimen (TEM; x2,000). (Sch=Schwann cell, My=myelin, Per=perineurium, Ep=epineurium, VW=vein wall).

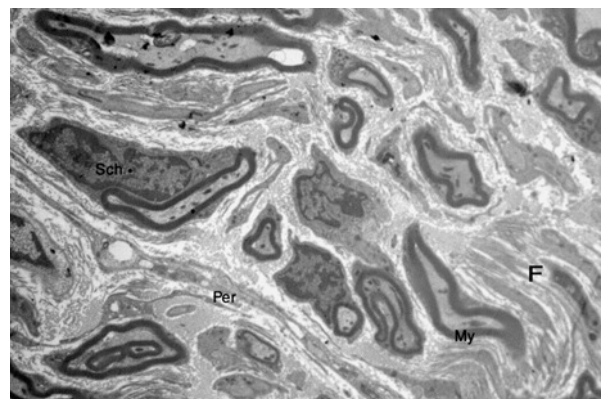


Fig. (7-C): Electron microscopic examination of the vein graft specimen (TEM; x10,000). (Sch=Schwann cell, My=myelin, Per=perineurium, F=fibroblast).

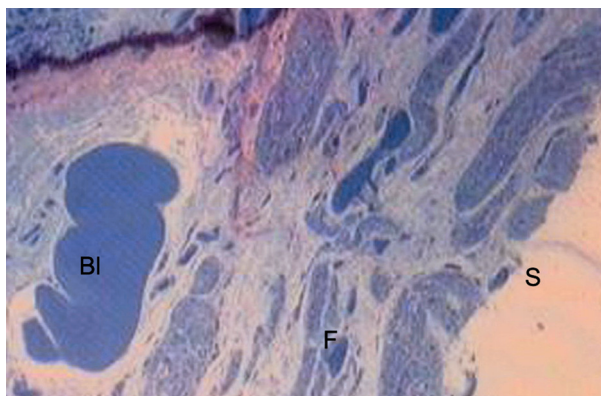


Fig. (8-A): Silicone tube (S) specimen. No evidence of neural tissue growth. Some fibroblasts (F), blood (Bl), and blood cells are noticed (LM, toluidine blue stain; x1,000).

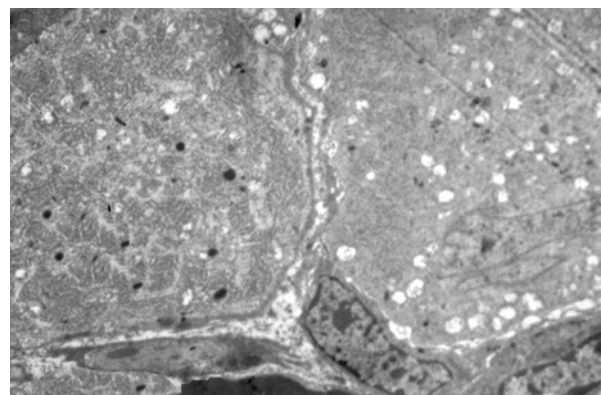


Fig. (8-B): Electron microscopic examination of the silicone tube specimen (TEM; x4,000). Nonspecific tissue is present.

*Histological examination:*

Sections were stained with 1% toluidine blue and examined with light microscope (oil-immersion objective) at x1000 magnification. Electron micrographs were used to assess the extent of myelinated and unmyelinated nerve fibers, and the degree of neo-vascularization (x2,000 to x10,000).

*Group I:* A well developed nerve structure with fibers arranged in minifascicular pattern of different sizes, the regenerated nerve was abundantly vascularized with numerous capillaries (Fig. 6-A).

*Group II:* Regenerated neural tissue was observed in the middle of the vein graft. It was enough vascularized with prominent perineurial bands subdividing the nerve into fascicles. An outer layer surrounding the epineurial-like element was noticed; the vein graft wall. It was observed-that-this outer layer was not compressing the regenerate, nor preventing its neovascularization. Some fibroblasts (scar tissue) were noticed in the center of specimen (Fig. 7-A).

*Group III:* There was no evidence of neural tissue in the center of the silastic tube. Some fibroblasts and blood cells were noticed (Fig. 8-A).

Electro microscopic findings paralleled the light microscopic ones (Figs. 6-B;7-B,C;8-B).

## DISCUSSION

Since the experimental animal work of Millesi [18] in late sixtieth on using nerve grafts to cross nerve defects, this technique has become the "gold standard" in surgical treatment of peripheral nerve loss. It is essential not to suture nerves under tension, even if minor [19]. So, nerve gap should be crossed with a suitable conduit whether a nerve graft (the standard) or an alternative one. Even though, autogenous nerve grafts are limited. Sural and medial cutaneous nerves of the forearm are the most popular grafts. Using such small grafts gives good results, while central necrosis may happen if thicker nerves are used [20]. This shall augment the assumption that the nerve graft should be in a suitably vascularized media to ensure its adequate nutrition. Again, we may resort to vascularized pedicled nerve graft whenever necessary [21]. Although various studies have reported complete restoration of function after autogenous nerve grafting, results are still far from being excellent [14,22].

Only a few important negative factors for neural healing can be minimized with the surgical tech-

nique. The surgeon should interfere as little as possible with the repair process, with minimal foreign substances and should allow the nerve tissue itself to form the only basis for cellular and chemical (neurotrophic factors) contributions for the regrowth [13,23]. Many experiments have demonstrated not only that neurotrophism exists, but that there is a high degree of specificity associated with this neurotrophism [24,25].

The ideal nerve repair would maximize any neurotrophic effects offered by the distal stump. The "state of art" microsurgical fascicular nerve repair might inhibit this potential neurotrophism by preventing the regenerating axons from determining "for themselves" the appropriate distal connections. The distance over which neurotrophic factors can exert their effects is unknown, but is properly finite. With too close an approximation of the two nerve ends, the benefits of the distal stump in directing appropriate regeneration may be lost. On the other extreme, if too long a distance exists, then the effects of these factors may be lost. Defects up to 10mm in rats' sciatic nerve are capable for regeneration through various nerve conduits [2,5,14].

In this study, our intension was to create an optimal physiological environment at the nerve defect site, to achieve proper regeneration with maximal neurotrophic effect. For this purpose, we crossed a 10-mm rat sciatic nerve defect with a 15mm autogenous vein or silicone conduit. A 10-mm nerve gap was chosen because the average length of the sciatic nerve trunk in our rat model is approximately 15mm and a larger gap would have made the microsurgical anastomoses difficult. This distance is in consistence with most published studies investigating the management of nerve gaps in animal models [11,26,27].

Autogenous vein grafts have been experimentally and clinically demonstrated to be supportive conduits for nerve fibers to regenerate and mature [11,26]. Veins are non immunogenic, cause less inflammatory reaction, are easier to be harvested than arteries, have a longer life than bioabsorbable tubes and are available in a wide variety of sizes [13]. The vein wall is thin, but resilient enough to act as a barrier against scar tissue ingrowing and permeable enough for proper nutrients diffusion to provide a favorable internal milieu for nerve growth. All three layers of the vein wall are rich in laminin, which is a high-molecular weight glycoprotein found in association with the basal lamina surrounding normal and traumatized nerve fibers. Laminin has neurite promoting properties and roles

in nerve cell adhesion, multiplication and differentiation and thus beneficially affects the velocity and direction of growth cone neurite [28].

In the current study, we used a 15-mm vein graft to cross the 10-mm neural gap. This graft is 5mm longer than previously published experiments. [11,13,28]. Neural regeneration was adequate in the center of the vein graft as compared with the conventional nerve graft. It formed an anatomically well defined multifasciculated neural tissue. Presence of some fibroblasts in few specimens did not interfere with the formation of such well organized neural tissue.

Rat studies had demonstrated regeneration distances across silicone tubes of only 5 to 10mm [15,29]. We used a 15-mm silicone tube to cross the rat sciatic nerve defect. No neural regeneration could be detected in the center of the tube. Also, disruption of the relatively firm silicone tube from the nerve stump has happened in some specimens. These findings may be related to the assumption that the non- absorbable conduits are impermeable and do not support the revascularization and oxygenation needed for proper neural regeneration [30]. Again, scarring and capsule formation that occurs around the silicone material may interfere with nerve growth and function; i.e. has inhibitory effect over neural regeneration [31]. These drawbacks stimulated researchers to use the pseudosheath that forms around the silicone tube as a conduit for nerve repair after removal of the tube [32,33]. It has the disadvantage of requiring two operative procedures: One to insert the tube and another one (6 weeks later) to remove the tube and implant the nerve ends into the vascularized pseudosheath.

As in other studies [26,34], we proved that a standard nerve graft is still superior to vein graft conduit based on our histological findings. Fibroblasts were detected in some cases of vein grafts, but not in nerve grafts. This shall invite investigators to do something with their neural conduits. Such as: 1) fabrication of synthetic absorbable materials that are biocompatible to react friendly with the neural tissue and completely reabsorbed after full neural regeneration, 2) tubes need to be of sufficient tensile strength to allow microsurgical adaptation to nerve stumps, 3) implant tubes have to resist compression, while flexible enough to prevent mechanical irritation, 4) the nerve guide wall should be semipermeable to guarantee sufficient fusion of oxygen and metabolites, without infiltration of scar forming fibroblasts and 5) filling of the nerve guides with neural growth factors

known to promote neural regeneration. Further improvement may be expected from integrating some self sustained biological component; such as, specific cells that not only function as biofactories for growth factors but also, respond to cell-cell signals that help to control these factors synthesis. Such biohybrid implants with cells are likely to implement feed back mechanisms that are automatically regulated by endogenous cell interactions.

Some limitations of this study could be noticed, they include an apparently short nerve gap, a relatively short time follow-up and the absence of clinical and electrophysiological assessment. The gap length is limited by the total length of the rat sciatic nerve. Although, we tried to override such short gap by using a longer graft (15mm), still a larger animal model would be necessary to study longer gaps. The data from this study have proved the good neural recovery through the venous conduit after 3 months. A longer follow-up shall elucidate more about the possible changes of neural regeneration inside specific conduits by time. Our histological study does not elaborate the clinical and electrophysiological outcomes of such proper neural healing. This should give more global idea about the effectiveness of that neural healing on functional recovery.

In conclusion, the results as observed in this study substantiate the merit of autogenous venous nerve conduit as biological non neural bridging graft for short nerve gaps and warrant its clinical application for human; especially, in short nerve defects. Numerous studies indicate that the short distance defects can be successfully managed by implantation of synthetic nerve guides. Bioabsorbable materials have many advantages than the non-absorbable ones. In the future, nerve guides might help to reduce the number of autogenous nerve transplantation with its inherent drawbacks. In addition, we expect progress in implants development because of the interdisciplinary approaches that are searching the materials and life sciences for advances that could improve the neuro-tissue engineering needed to effectively treat longer nerve defects.

## REFERENCES

- 1- Mackinnon S.E.: Surgical management of peripheral nerve gap. *Clin. Plast. Surg.*, 16: 587, 1989.
- 2- Fields R.D., LeBeau J.M., Longo F.M. and Ellisman M.H.: Nerve regeneration through artificial tubular implants. *Prog. Neurobiol.*, 33: 87, 1989.
- 3- Ide C., Osawa T. and Tohyama K.: Nerve regeneration through allogeneic nerve grafts with special reference to

- the role of Schwann cell basal lamina. *Prog. Neurobiol.*, 34: 1, 1990.
- 4- Snider W.D. and Johnson E.M.: Neurotrophic molecules. *Ann. Neurol.*, 26: 489, 1989.
  - 5- Rich K.M., Luszczyński J.R., Osborne P.A. and Johnson E.M.: Nerve growth factor protects adult sensory neurons from cell death and atrophy caused by nerve injury. *J. Neurocytol.*, 16: 261, 1987.
  - 6- Bungner O.V.: Ueber die degenerations-und-regenerationsvorgänge am nerven nach verletzungen. *Beitr. Pathol. Anat.*, 10: 321, 1891.
  - 7- Platt H.: On the results of bridging gaps in injured nerve trunks by autogenous facial tubulization and autogenous nerve graft. *Br. J. Surg.*, 7: 384, 1919.
  - 8- Stopford J.S.B.: The treatment of large defects in peripheral nerve injuries. *Lancet*, 2: 1296, 1920.
  - 9- Gibb A.G.: Facial nerve sleeve graft. *J. Laryngol. Otol.*, 84: 577, 1970.
  - 10- Chiu D.T.W., Janecka I., Krizek T.J., Wolff M. and Lovelace R.E.: Autogenous vein graft as a conduit for nerve regeneration. *Surg. Forum*, 31: 550, 1980.
  - 11- Chiu D.T.W., Janecka I., Krizek T.J., Wolff M. and Lovelace R.E.: Autogenous vein graft as a conduit for nerve regeneration. *Surgery*, 91: 226, 1982.
  - 12- Rice D.H. and Berstein F.D.: The use of autogenous vein for nerve grafting. *Otolaryngol. Head Neck Surg.*, 92: 410, 1984.
  - 13- Foidart-Desalle M., Dubuisson A., Lejeune A., Severyns A., Manassis Y., Delree P., Crielard J.M., Bassleer R. and Lejeune G.: Sciatic nerve regeneration through venous or nervous grafts in the rat. *Exp. Neurol.*, 148: 236, 1997.
  - 14- Schlosshauer B., Dreesmann L., Schaller H.E. and Sinis N.: Synthetic nerve guide implants in humans: A comprehensive survey. *Neurosurg.*, 59: 740, 2006.
  - 15- Lundborg G.: Nerve regeneration and repair: A review. *Acta. Orthop. Scand.*, 58: 145, 1987.
  - 16- Chen Y.S., Wang-Bennett T.L.T. and Coker N.J.: Facial nerve regeneration in the silicone chamber: The influence of nerve growth factor. *Exp. Neurol.*, 103: 52, 1989.
  - 17- Williams L.R., Danielsen B., Muller H. and Varon S.: Exogenous matrix precursors promote functional nerve regeneration across a 15-mm gap within a silicone chamber in the rat. *J. Comp. Neurol.*, 264: 284, 1987.
  - 18- Millesi H.: Nerve transplantation for reconstruction of peripheral nerves injured by the use of the microsurgical technique. *Minerva Chir.*, 22: 950, 1967.
  - 19- Navissano M., Malan F., Carnino R. and Battiston B.: Neurotube for facial nerve repair. *Microsurgery*, 25: 268, 2005.
  - 20- Matsuyama T., Mackay M. and Midha R.: Peripheral nerve repair and grafting techniques: A review. *Neurol. Med. Chir.*, 40: 187, 2000.
  - 21- Dickinson J.C. and Bailey B.N.: Island pedicled nerve grafts. *Br. J. Plast. Surg.*, 42: 573, 1989.
  - 22- Samardzic M.M., Rasulic L.G. and Grujicic D.M.: Results of cable graft technique in repair of large nerve trunk lesions. *Acta Neurochir.*, 140: 1177, 1998.
  - 23- Dahlin L.B. and Lundborg G.: Use of tubes in peripheral nerve repair. *Neurosurg. Clin. North Am.*, 12: 341, 2001.
  - 24- Mackinnon S.E., Dellon A.L., Lundborg G., Hudson A.R. and Hunter D.A.: A study of neurotrophism in a primate model. *J. Hand Surg. (Am.)*, 11: 888, 1986.
  - 25- Brushart T.M. and Seiler W.A.: Selective reinnervation of distal motor stumps by peripheral motor axons. *Exp. Neurol.*, 97: 289, 1987.
  - 26- Suematsu N., Atsuta Y. and Hirayama T.: Vein graft for repair of peripheral nerve gap. *J. Reconstr. Microsurg.*, 4: 313, 1988.
  - 27- Pu L.L., Syed S.A., Reid M., Patwa H., Goldstein J.M., Forman D.L. and Thomson J.G.: Effects of nerve growth factor on nerve regeneration through a vein graft across a gap. *Plast. Reconstr. Surg.*, 104: 1379, 1999.
  - 28- Thanos P.K., Okajima S. and Terzis J.K.: Ultrastructure and cellular biology of nerve regeneration. *J. Reconstr. Microsurg.*, 14: 423, 1998.
  - 29- Rich K.M., Alexander T.D., Pryor J.C. and Hollowell J.P.: Nerve growth factor enhances regeneration through silicone chambers. *Exp. Neurol.*, 105: 1, 1989.
  - 30- Mackinnon S.E., Dellon A.L., Hudson A.R. and Hunter D.A.: Chronic nerve compression: An experimental model in the rat. *Ann. Plast. Surg.*, 13: 112, 1984.
  - 31- Mackinnon S.E., Dellon A.L., Hudson A.R. and Hunter D.A.: A primate model for chronic nerve compression. *J. Reconstr. Microsurg.*, 1: 185, 1985.
  - 32- Mackinnon S.E., Dellon A.L., Hudson A.R. and Hunter D.A.: Nerve regeneration through a pseudosynovial sheath in a primate model. *Plast. Reconstr. Surg.*, 75: 833, 1985.
  - 33- Mackinnon S.E. and Dellon A.L.: A comparison of nerve regeneration across a sural nerve graft and a vascularized pseudosheath. *J. Hand Surg. (Am.)*, 13: 935, 1988.
  - 34- Chiu D.T.W. and Strauch B.: A prospective clinical evaluation of autogenous vein grafts used as a nerve conduit for distal sensory defects of 3cm or less. *Plast. Reconstr. Surg.*, 86: 928, 1990.